


PATIENT

 Neptune Burlington
 HS

SPECIES

Feline

BREED

DSH

SEX

Male Intact

AGE

4 months

WEIGHT

4.2lbs

INTERPRETED BY

 Maggie Machen Lamy,
 DVM DACVIM
 (Cardiology)

**IMAGING
 PERFORMED BY**

Kelly Reschny, RVT

HOSPITAL NAME

 Burlington Humane
 Society

REFERRING VET

Dr. Wallace

INVOICE

31259

DATE

6/9/23

PRESENTING CLINICAL SIGNS

History: Grade 1-2/6 heart murmur.

ECHOCARDIOGRAM FINDINGS

2D, m-mode, color flow and doppler imaging is available. The left ventricular wall is normal in dimension. There is a mildly hyperechoic endocardium. The papillary muscles are normal in dimension and appearance. The left atrium is normal in size. The right atrium is normal in size. The right ventricle appears normal. The mitral valve is normal in structure and mobility. Blood flow through both the LVOT and RVOT is normal in velocity. No obvious congenital defects. No pleural or pericardial effusion seen. No obvious cardiac tumors.

CARDIAC CHART

FELINE CARDIAC PARAMETERS	BODY WEIGHT (kg)	HR (BPM)	IVSd (cm) <small>(Moise, Pipers)</small>	LVIDd (cm) <small>(Moise, Pipers)</small>	LVWd (cm) <small>(Moise, Pipers)</small>	FS (%)	EF (%)
NORMAL PARAMETER	-----	150-240	0.35-0.55	<2 (mean 1.5)	3.5-0.55	35-67	80-100
PATIENT	1.9	160	0.35	1.43	0.37	50	92
FELINE CARDIAC PARAMETERS	LA/AO <small>(Boon)</small>	LA/AO HEART BASE (Swe) <small>(Abbott)</small>	LA 2D short axis Base view (cm) <small>(Abbott)</small>	LVOT VEL <small>(m/s)</small>	RVOT VEL <small>(m/s)</small>	E max <small>(m/s)</small>	
NORMAL	<1.5	<1.3	<1.2	<1.6	<1.3	<0.9	
PATIENT	1.2	1.2	0.9	0.94	1.1	NM	
<i>*Note: All measurements based upon multi-modal images and methods. An average value is reported.</i> Adapted from June Boon, Veterinary Echocardiography, 1998 Abbott J & MacLean H JVIM 2006;20: 111-119, Moise et al. Am J Vet Res 47:1476, 1986. Pipers et al. Am J Vet Res 40:882, 1979.							

INTERPRETATION OF THE FINDINGS & FURTHER RECOMMENDATIONS

Overtly normal cardiac structure and function. The LV wall thickness is normal and there is no evidence of elevated left atrial pressure. Additionally, no cause for the murmur is identified in this study, making it likely physiologic in origin (i.e., secondary to tachycardia, volume changes, etc.) potentially masked by sedation. That being said, it is important to note that small abnormalities are easily missed, particularly in juvenile patient. If the murmur persists or progresses as the kitten ages, referral to a local Cardiologist for advanced imaging would be reasonable.

Given these findings, no medications are indicated.

No cardiac contraindication for general anesthesia.

Assuming the murmur persists, consider referral as discussed. If declined, recheck echocardiogram in 6-12 months to reassess murmur origin.



PATIENT

Neptune Burlington
HS

SPECIES

Feline

BREED

DSH

SEX

Male Intact

AGE

4 months

WEIGHT

4.2lbs

INTERPRETED BY

Maggie Machen Lamy,
DVM DACVIM
(Cardiology)

**IMAGING
PERFORMED BY**

Kelly Reschny, RVT

HOSPITAL NAME

Burlington Humane
Society

REFERRING VET

Dr. Wallace

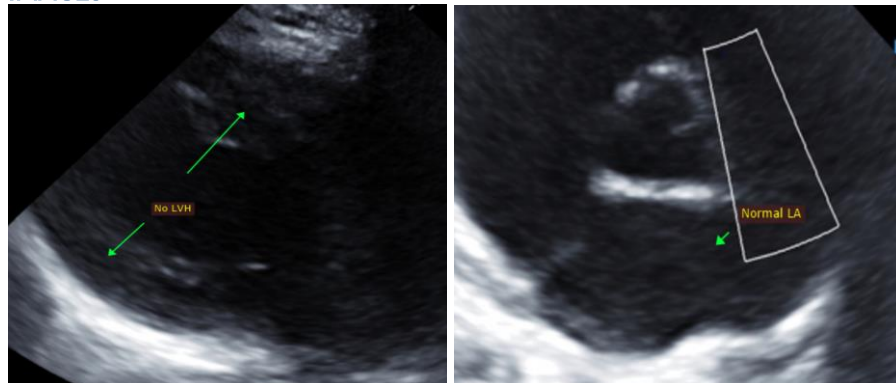
INVOICE

31259

DATE

6/9/23

IMAGES



The information and recommendations provided are based on the images presented by the referring veterinarian. No evaluation can be communicated regarding pathology that was not visible in the image/video clips provided.

Thank you for this referral. This report was generated using transcription software, and minor dictation errors may be present. If the clinical or image interpretation does not parallel your findings or if I can be of any further assistance, please contact me.

Maggie Machen Lamy, DVM
Diplomate of the American College of Veterinary Internal Medicine (Cardiology)
info@sonopath.com